

State of the Art in the Treatment of Achilles Tendon Ruptures (ATR)

Early Protected Weightbearing for Acute Ruptures of the Achilles Tendon: Do Commonly Used Orthoses Produce the Required Equinus?

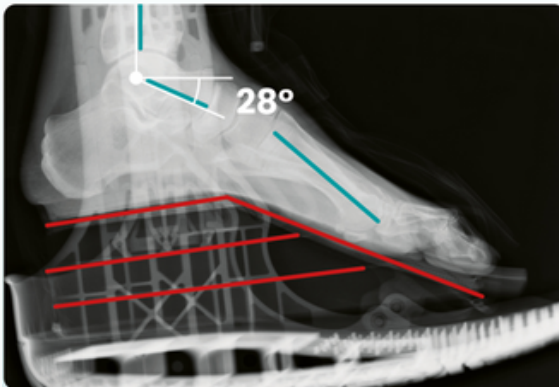
P. Ellison, A. Molloy, L. W. Mason – Aintree University Hospital

The Journal of Foot & Ankle Surgery 2017, vol. 56, issue 5, pp. 960–963. DOI: <http://dx.doi.org/10.1053/j.jfas.2017.06.017>.

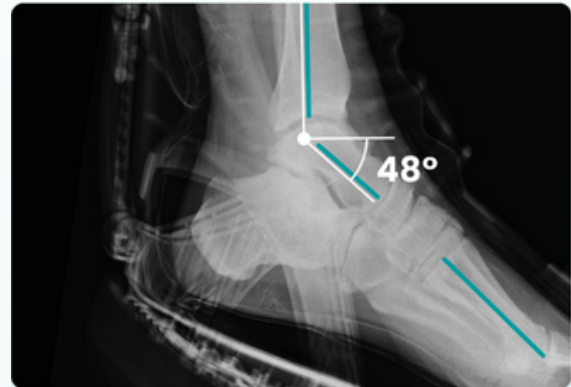


Background

A comparison of the tibio talar and tibio-1st metatarsal angles in two different walking orthoses by lateral radiograph.



orthosis with wedges



vacuum orthosis (VACOped)

Results

As images confirm, caution should be used in the use of wedges (as may not produce sufficient ankle equinus to shorten Achilles tendon during healing) which may result in tendon elongation, and therefore:

- Reduced plantar flexion power
- Reduced function and patient outcomes

The treatment of a rupture of the Achilles tendon using a dedicated management programme



A. M. Hutchison, C. Topliss, D. Beard, R. M. Evans, P. Williams – Morriston Hospital

Bone Joint J 2015; 97-B:510–15. DOI: 10.1302/0301-620X.97B4.35314.

Summary of the SMART (Swansea Morriston Achilles Rupture Treatment) programme

A retrospective analysis 2008 – 2014.

273 patients with an acute rupture treated (211 conservatively, 62 surgically) using the SMART programme which involves ultrasound examination, accelerated exercise regime with individual goal orientated progression and return to work & sports, early functional weight-bearing using the VACOped with a defined range of movement (ROM), held within a dedicated Achilles clinic.

Results

- Low rerupture rate (1.1%)
- Great functional outcomes
- Reduced requirements for surgical intervention
- Cost saving of £91,000 per annum

The SMART Protocol

Treatment week	1	2	3	4	5	6	7	8	9	10	11	12
SMART Protocol ATR (conservative & operative treatment)	Equinus POP	Equinus POP	VACOped 30°	VACOped 30°	VACOped 15°-30°	VACOped 15°-30°	VACOped 0°-30°	VACOped 0°-30°	VACOped -15°-30°	VACOped -15°-30°	Wear from orthosis	Wear from orthosis
Phase 1	non-weightbearing	non-weightbearing	weightbearing as tolerated	weightbearing as tolerated	weightbearing as tolerated	weightbearing as tolerated	weightbearing as tolerated	weightbearing as tolerated	weightbearing as tolerated	weightbearing as tolerated	weightbearing as tolerated	weightbearing as tolerated
Phase 2	non-weightbearing	non-weightbearing	weightbearing as tolerated	weightbearing as tolerated	weightbearing as tolerated	weightbearing as tolerated	weightbearing as tolerated	weightbearing as tolerated	weightbearing as tolerated	weightbearing as tolerated	weightbearing as tolerated	weightbearing as tolerated
Phase 3	non-weightbearing	non-weightbearing	weightbearing as tolerated	weightbearing as tolerated	weightbearing as tolerated	weightbearing as tolerated	weightbearing as tolerated	weightbearing as tolerated	weightbearing as tolerated	weightbearing as tolerated	weightbearing as tolerated	weightbearing as tolerated
				Open range of motion for joint mobility	Open range of motion for joint mobility	Open range of motion for joint mobility	Open range of motion for joint mobility	Open range of motion for joint mobility	Open range of motion for joint mobility	Open range of motion for joint mobility	Open range of motion for joint mobility	Open range of motion for joint mobility
				Fixed at 90°	Fixed at 90°	Fixed at 90°	Fixed at 90°	Fixed at 90°	Fixed at 90°	Fixed at 90°	Fixed at 90°	Fixed at 90°
				Physiotherapy	Physiotherapy	Physiotherapy	Physiotherapy	Physiotherapy	Physiotherapy	Physiotherapy	Physiotherapy	Physiotherapy
				Achill-sole	Achill-sole	Achill-sole	Achill-sole	Achill-sole	Achill-sole	Achill-sole	Achill-sole	Achill-sole

Non-operative functional treatment for acute Achilles tendon ruptures: The Leicester Achilles Management Protocol (LAMP)



Randeep S. Aujla, Shakil Patel, Annette Jones, Maneesh Bhatia

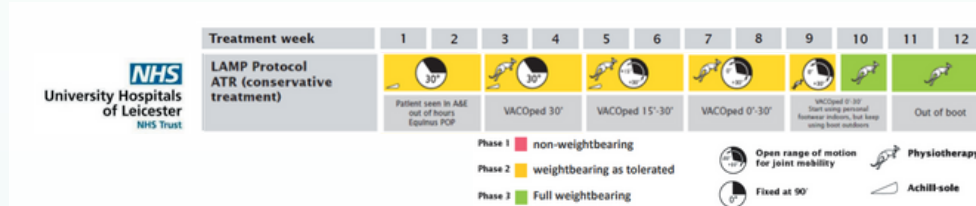
Trauma & Orthopaedic Surgery, University Hospitals of Leicester, Leicester, United Kingdom *Injury* 2019 Apr; 50(4): 995-999.
Doi: 10.1016/j.injury.2019.03.007

Summary

Study with 442 patients with acute Achilles tendon (AT) ruptures treated conservatively with an eight-week functional dynamic treatment protocol including the use of dynamic range of movement (dROM) in a VACoped boot with immediate full weight bearing mobilisation, and utilisation of ATRS Scoring.

Results

Equal quality of functional results (ATRS 75.5) as SMART without initial casting. Recovery in 8 weeks. Low re-rupture rate (2%), Low number of complications. Simple, reliable and cost effective regime, that can be adopted universally.



Functional outcome of early weightbearing for acute Achilles tendon rupture treated conservatively in a weight-bearing orthosis



R Naskar, L. Oliver, P. Velazquez-Ruta, B. Dhinsa, C. Southgate

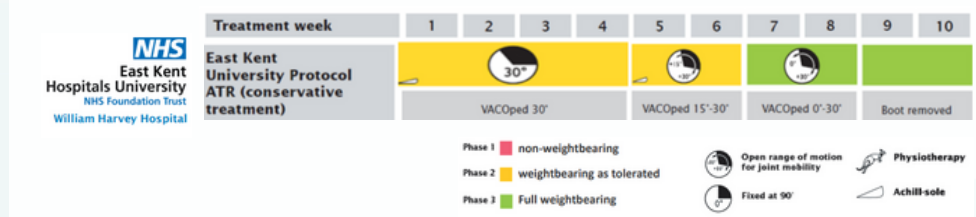
East Kent Hospital, UK *Foot Ankle Surg.* 2021 Jul 2; S1268-7731(21)00138-7. Doi: 10.1016/j.fas.2021.06.008

Summary

Study with 41 patients investigating the functional outcomes of early weight bearing in a functional orthosis including the use of dynamic range of movement (dROM) for conservatively managed, complete AT ruptures with a gap up to 5 cm.

Results

Equal results compared to LAMP and SMART but also without initial casting and for gaps up to 5 cm. Excellent functional results with ATRS of 82.1, low rerupture rate (1 patient), no other complications, excellent patient satisfaction.



Functional weight-bearing mobilization after Achilles tendon rupture enhances early healing response: a single-blinded randomized controlled trial



K.P. Valkering, S. Aufwerber, F. Ranuccio, E. Lunini, G. Edman, P.W. Ackermann

Karolinska University Hospital Sweden - Knee Surgery, Sports Traumatology, Arthroscopy, 2016 August 18

Summary

A randomised controlled trial of 56 patients across two groups following operative treatment of an acute Achilles rupture, with the objective to measure the concentration of metabolites in the peritendineum to determine healing rates. Group 1 using the VACoped with a defined range of motion protocol, group 2 using an Aircast walker with a 3 wedge system protocol. Both groups were fully weight bearing (with crutches to start) and range of motion exercises were prescribed to both groups. Measurements taken at 2 weeks using microdialysis and functional assessments done at 6 & 12 months

Results

Significantly higher glutamate levels recorded in the VACoped group along with better mobilisation through the ankle joint compared to the immobilised group. In conclusion it was measured that full weight bearing and functional mobilisation resulted in an early improved healing response when measured against patients treated with immobilisation.